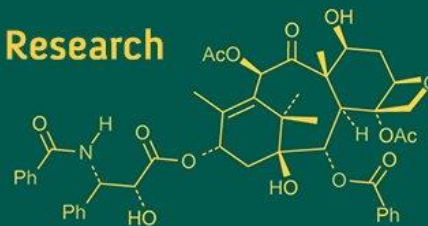
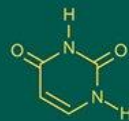
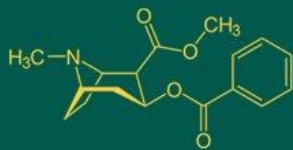


## International Journal of Advanced Biochemistry Research



ISSN Print: 2617-4693  
ISSN Online: 2617-4707  
IJABR 2019; 3(1): 04-06  
www.biochemjournal.com  
Received: 04-11-2018  
Accepted: 05-12-2018

**Eslam Elfeky**  
Student of Master Degree,  
Faculty of Science, Zoology  
Department, Port Said  
University, Egypt

**Ahmed Khalaf**  
Lecturer of Physiology,  
Faculty of Science, Zoology  
Department, Port Said  
University, Egypt

**Osama Abaas**  
Professor of physiology,  
Faculty of Science, Zoology  
Department, Port Said  
University, Egypt

**Mohamed Hefny**  
Professor & Head of Physical  
Medicine, Rheumatology &  
Rehabilitation Department,  
Faculty of Medicine, Suez  
Canal University, Egypt

**Correspondence**

**Eslam Elfeky**  
Student of Master Degree,  
Faculty of Science, Zoology  
Department, Port Said  
University, Egypt

## Histological study on freund's complete adjuvant induced arthritis in rat models following treatment with crude Egyptian scorpion venom and methotrexate

**Eslam Elfeky, Ahmed Khalaf, Osama Abaas and Mohamed Hefny**

**Abstract**

The therapeutic application of scorpion venom (SV), has been used in traditional medicine. SV contains a variety of peptides that can treat variety of diseases, such as arthritis, rheumatism, pain, cancerous tumors, and skin diseases. Methotrexate (MTX) is a nonsteroidal anti-inflammatory drug (NSAID). It works by reducing hormones that cause inflammation and pain in the body. MTX is used to treat moderate to severe osteoarthritis, rheumatoid arthritis, gouty arthritis, or ankylosing spondylitis. MTX is also used to treat shoulder pain caused by bursitis or tendinitis. Histological observations showed that diseased groups have edematous, thickened, and hyperplastic synovium membrane with reduction in joint space and empty lacunae appeared. On the other hand, scorpion venom high dose and Methotrexate caused reduction in size of synovium and regression of its inflammatory cell infiltrate with lacunae occupied appeared.

**Keywords:** Scorpion venom (SV), Freund's complete adjuvant (FCA), rheumatoid arthritis (RA), methotrexate (MTX)

**Introduction**

Rheumatoid arthritis (RA) is characterized by polyarthritis but particularly attacks synovial joints, manifested chronic pain and joint malformation, leading to synovial hyperplasia and progressive cartilage and bone destruction [1], and loss of function and mobility if not properly treated. The medicines that are currently used for treatment of RA may be roughly included in three categories: disease modifying anti-rheumatic drugs, non steroidal anti-inflammatory drugs, and steroid [2, 3]. However, these drugs are undesirable for prolonged treatments due to their poor efficacy, delayed onset of action, high cost, long-term side effects, and toxicity [3, 4]. Therefore, much effort has been put into screening new therapeutic agents from natural products in the hope to reduce the risk of adverse events and slow down the progression of the disease [5].

Scorpion peptides possess both toxic and therapeutic action; they release the neurotransmitters by acting on sodium and potassium channels [6]. Scorpion extracts are also used to treat epilepsy, facial paralysis, pain, and rheumatism. Bm K IT-AP and Bm K dIT-AP3 are the peptides isolated from *Buthus martensi* Karsch scorpion possess analgesic activity [7]. The scorpion toxins composition and venom potency are different from species to species [8]. The objective of the present study included the observations of the histological modification occurred in joint tissues before and after treatments with Egyptian scorpion venom and Indomethacin.

**Material and Methods****Chemicals**

- Freund's complete adjuvant procured from Sigma-Aldrich.
- Marketed preparations of MTX was used.

**Scorpion venom**

Scorpion venom was obtained from electrical stimulation of telson of the tail

**Freund’s complete adjuvant induced arthritis**

Freund’s complete adjuvant (FCA) was prepared by suspending in liquid paraffin. The arthritis was induced by a single subcutaneous injection of 0.05 ml of FCA into the left hind metatarsal footpad of rat [9]. FCA produced definite edema within 24 h with progressive arthritis by day 10 after inoculation. In therapeutic model animals were treated from day 14 to 30 day.

**Animal groups design**

35 wistar albino rats were divided into 5 groups, 7 in each group.

**Group I:** Control Negative (without injection with FCA)

**Group II:** Arthritic control (Disease control)

**Group III:** Methotrexat stranded treated group 0.3mg/kg sub cutaneously.

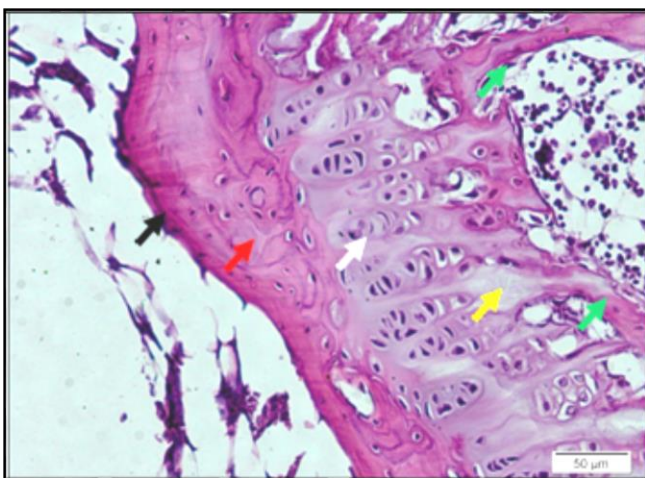
**Group IV:** SV treated group low dose and high dose subcutaneously.

For histopathology, proximal interphalangeal joints were taken from five rats of each group and processed to form paraffin blocks. For preparation of paraffin blocks, digits were removed, ankles joints were fixed in 10% buffered formalin. Decalcification in 5% nitric acid was done, and then specimens were dehydrated, cleared and embedded in paraffin wax. Sectioning was done at 5µm thickness. Obtained sections were stained with hematoxylin and eosin stain (H&E).

**Results**

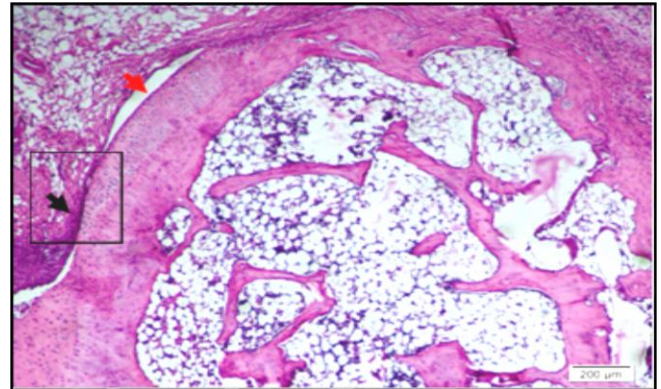
Microscopic examination for eosin and hematoxylin (E&H) stained sections from joints of normal control, arthritic, SV low dose, SV high dose and MTX treated group.

**Normal control group:** As presented in figures (1), joints of normal control group showed the articular cartilage with its zones to compare it with arthritic and treated groups.



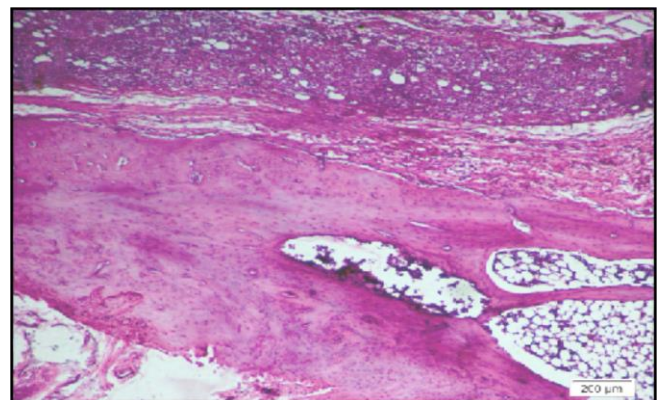
**Fig 1:** T.S in joint of normal control rat. The articular cartilage with its zones: a superficial tangential zone (Black arrow); a transitional zone (Red arrow) that contained scattered chondrocytes; a radial zone (White arrow) containing chondrocytes arranged perpendicular to the surface; and a calcified zone (Yellow arrow) separating the hyaline cartilage from the underlying subchondral bone (Green arrow).

**Arthritic Groups:** Joints of non treated arthritic group in figure (2) showed edematous, thickened, and hyperplastic synovium membrane. The synovium membrane begin to form Pannus which is composed of diffuse chronic inflammatory infiltrate, the space of joints appear very small.



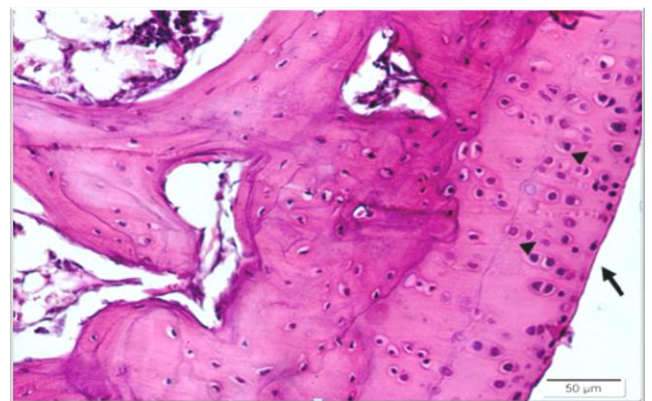
**Fig 2:** The synovium membrane is edematous, thickened, and hyperplastic, and grew over the surface of the articular cartilage (Pannus) (Black arrow), with reduction in joint space (Red arrow).

**SV low dose**



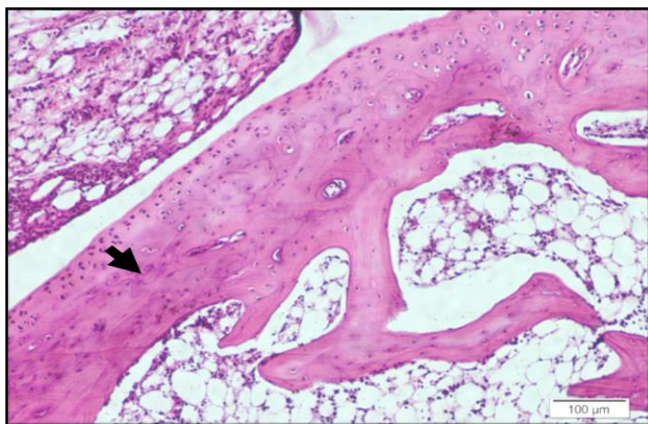
**Fig 3:** No improvement could be observed in hyperplastic chronically inflamed synovium membrane.

**High dose scorpion venom:** joints of SV high dose treated group in figures (4), revealed that reduction in size of synovium and regression of its inflammatory cell infiltrate. No empty lacunae appeared.



**Fig 4:** Most areas of articular cartilage show smooth uniform outer surface (Black arrow), with restoration of its zones, and with regular arrangement of uniform chondrocytes (Arrow heads) with occupied lacunae.

**Methotrexate treated group:** Joints of MTX treated group in figures (5) revealed reduction in size of synovium with marked regression of its inflammatory cell infiltrate and thus disappearance of the pannus. The joint space is restored and The underlying articular cartilage show partial restoration of its zones, but with irregular arrangement of chondrocytes which show mild degenerative pyknotic eccentric nuclei.



**Fig 5:** The synovium (Black arrow) shows marked reduction in size, regression of its inflammatory cell infiltrate and thus disappearance of the pannus.

### Discussions

The observed histopathological changes of proximal interphalangeal joints of the experimental groups reveals that, disease control group of arthritic rats joint showed prominent abnormalities from the normal joint like edema formation, degeneration with partial erosion of the cartilage, destruction of bone marrow and extensive infiltration of inflammatory exudates in the articular surface. These observations were in agree to those were demonstrated by Bauerova, Paulovicova<sup>[10]</sup> and Xie, Ma<sup>[11]</sup> and Makhlof, Khalil<sup>[12]</sup>. The standard treated group joint showed normal bone marrow with less cellular infiltrates. SV treated groups had less inflammatory signs like scanty cellular infiltrate, absence of edema formation and normal bone marrow, whereas less cartilage destruction in FCA models.

### References

1. Andreas K *et al.* Key regulatory molecules of cartilage destruction in rheumatoid arthritis: an *in vitro* study. *Arthritis research & therapy.* 2008; 10(1):R9.
2. O'dell JR. Therapeutic strategies for rheumatoid arthritis. *New England Journal of Medicine.* 2004; 350(25):2591-2602.
3. Kim KR *et al.* Red ginseng saponin extract attenuates murine collagen-induced arthritis by reducing pro-inflammatory responses and matrix metalloproteinase-3 expression. *Biological and Pharmaceutical Bulletin.* 2010; 33(4):604-610.
4. Scott D, Kingsley G. Tumor necrosis factor inhibitors for rheumatoid arthritis. *New England Journal of Medicine.* 2006; 355(7):704-712.
5. Karatas A *et al.* Pemetrexed ameliorates experimental arthritis in rats. *Inflammation.* 2015; 38(1):9-15.
6. Ahmadi M *et al.* Study on anti inflammatory effect of scorpion (*Mesobuthus eupeus*) venom in adjuvant-induced arthritis in rats. *Archives of Razi Institute.* 2009; 64(1):51-56.
7. Rajendra W, Armugam A, Jeyaseelan K. Toxins in anti-nociception and anti-inflammation. *Toxicon.* 2004; 44(1):1-17.
8. Borges A *et al.* Diversity of long-chain toxins in *Tityus zuluianus* and *Tityus discrepans* venoms (*Scorpiones, Buthidae*): molecular, immunological, and mass spectral analyses. *Comparative Biochemistry and Physiology Part C: Toxicology & Pharmacology.* 2006; 142(3-4):240-252.
9. Wei W, Chen M, Xu S. Pharmacological effects of isoxicam. *Chin Pharmacol Bull.* 1986; 2:29-34.
10. Bauerova K *et al.* Combined methotrexate and coenzyme Q10 therapy in adjuvant-induced arthritis evaluated using parameters of inflammation and oxidative stress. *Acta Biochimica Polonica.* 2010; 57(3):347.
11. Xie C *et al.* SKLB023 blocks joint inflammation and cartilage destruction in arthritis models via suppression of nuclear factor-kappa B activation in macrophage. *PLoS one.* 2013; 8(2):e56349.
12. Makhlof NA, Khalil WF, Farghaly LM. The possible therapeutic effect of 'Chaetomium globosum' fungal extract on experimentally induced rheumatoid arthritis. *Egyptian Journal of Histology.* 2013; 36(4):964-978.
13. Kennedy A *et al.* Angiogenesis and blood vessel stability in inflammatory arthritis. *Arthritis & Rheumatology.* 2010; 62(3):711-721.
14. Sadick H *et al.* Angiogenesis in hereditary hemorrhagic telangiectasia: VEGF165 plasma concentration in correlation to the VEGF expression and microvessel density. *International Journal of Molecular Medicine.* 2005; 15(1):15-19.
15. Cao Z *et al.* Tumor cell-mediated neovascularization and lymphangiogenesis contrive tumor progression and cancer metastasis. *Biochimica et Biophysica Acta (BBA)-Reviews on Cancer.* 2013; 1836(2):273-286.