

ISSN Print: 2617-4693
 ISSN Online: 2617-4707
 IJABR 2024; SP-8(5): 49-51
www.biochemjournal.com
 Received: 25-03-2024
 Accepted: 30-04-2024

V Mahesh
 Assistant Professor,
 Department of Veterinary
 Surgery and Radiology,
 Veterinary College,
 Hebbal, Bengaluru,
 Karnataka, India

Chandana L
 Department of Veterinary
 Surgery and Radiology,
 Veterinary College, Hebbal,
 Bengaluru, Karnataka, India

Vidhyashree GA
 Department of Veterinary
 Surgery and Radiology,
 Veterinary College, Hebbal,
 Bengaluru, Karnataka, India

Azeefa Fakaruddin Mujawar
 Department of Veterinary
 Gynaecology and Obstetrics,
 Veterinary College, Hebbal,
 Bengaluru, Karnataka, India

Corresponding Author:
V Mahesh
 Assistant Professor,
 Department of Veterinary
 Surgery and Radiology,
 Veterinary College,
 Hebbal, Bengaluru,
 Karnataka, India

Gastrotomy for retrieval of pressure cooker weight in a dog: A case report

V Mahesh, Chandana L, Vidhyashree GA and Azeefa Fakaruddin Mujawar

DOI: <https://doi.org/10.33545/26174693.2024.v8.i5Sa.1128>

Abstract

A eight-month-old, male Labrador Retriever dog was presented to the Veterinary College Hospital, Bengaluru, with a history of anorexia and vomiting since three days. Physical examination revealed pale mucous membrane and normal body temperature. On abdominal examination, a hard mass was palpated in the cranioventral abdominal region and animal evinced pain. Abdominal palpation confirmed presence of a gastric foreign body, which was retrieved surgically through gastrotomy under general anesthesia. Post-operatively, the dog recovered uneventfully.

Keywords: Labrador retriever dog, gastric foreign body, pressure cooker weight, gastrotomy

1. Introduction

A gastric foreign body is anything ingested by an animal that cannot be digested like rocks, plastic or that is slowly digested like bones. The playful nature of young dogs or puppies usually increases the risk of ingesting foreign objects (Kumar *et al.*, 2000; Capak *et al.*, 2001; Papazoglou *et al.*, 2003) [8, 2, 10]. There have been many reports of foreign bodies, such as rubber, metallic, plastic, or stone particles, obstructing the gastrointestinal tract (Koike *et al.*, 1981; Raghunath *et al.*, 2016; Mahesh *et al.*, 2019) [7, 12, 9]. The pylorus is the most frequently obstructed location in cases of gastric foreign substances. The most reliable diagnostic procedure for radio dense and radiopaque foreign bodies is radiographic study and endoscopy respectively. Surgical removal is necessary if these objects fail to pass within 48 hours and if the clinical signs deteriorates, followed by serial radiographic evidence that the objects are not moving (Harari., *loc. cit*). In the present report, we put forth successful retrieval of non-linear foreign body i.e., pressure cooker weight from stomach by performing gastrotomy in a Labrador Retriever dog.

2. Materials and Methods

An 8-month-old male Labrador Retriever dog weighing around 14 kg was presented to the Department of Surgery and Radiology, Veterinary College, Bengaluru, with a history of anorexia, vomiting and progressive loss of weight in the last 2 weeks. Clinically, the pet was dull, dehydrated with pale mucous membranes and all physiological parameters were in normal range. On abdominal palpation, animal evinced pain and hard mass was palpated. Radiographic examination confirmed the presence of non-linear foreign body in the cranio-ventral abdominal cavity. Hematological and biochemical parameters were within normal range except elevated total leukocytic counts. An emergency exploratory laparotomy was planned to be performed.

Animal was premedicated with Atropine sulphate (0.04 mg/kg b. wt.) and Xylazine hydrochloride (1 mg/kg b. wt.) administered intramuscularly. Ceftriaxone (25 mg/kg b. wt.) and Meloxicam (0.2 mg/kg b. wt.) were given subcutaneously as pre-emptive antibiotic and analgesic respectively. General anaesthesia was induced and maintained with 2.5% Thiopentone sodium (12.5 mg/kg b. wt.) intravenously. The ventral abdomen was prepared aseptically by restraining the animal in dorsal recumbency. Ventral midline abdominal incision was made from the xiphoid to two centimeters caudal to umbilicus. Entire abdominal contents were inspected before incising the stomach. To reduce contamination, stomach was isolated from remaining abdominal contents to the incised site.

A full thickness linear incision was made on the ante mesenteric border avoiding major blood vessels and cooker whistle weight was removed using alleys forceps. The stomach was subsequently flushed with warm normal saline prior to closure. A simple continuous suture pattern was used to close the inner gastric layer followed by a simple interrupted pattern for the muscularis externa and serosal layers of the stomach using chromic catgut no.2-0. The midline incision site was closed by suturing Linea alba with vicryl no.1 using simple interrupted suture pattern. Subcutaneous tissue was sutured using vicryl no.1 by simple continuous suture pattern and skin was sutured using trulon no.1 horizontal mattress suture pattern. Postoperatively, intravenous fluid therapy using Ringers Lactate (10mg/kg b. wt.), Dextrose Normal Saline (10mg/kg b. wt.) and Metronidazole (15mg/kg b. wt.) twice a day along with intravenous administration of Pantoprazole (1mg/kg b. wt.), Ondansetron (0.5mg/kg b. wt.), Ceftriaxone (25 mg/kg b. wt.) and Meloxicam (0.3 mg/kg b. wt.) was given. Oral feeding was avoided for 5 days. Wound dressing was done on alternate day. Sutures were removed on 14th post-operative day and the animal recovered uneventfully.

3. Results and Discussion

Indiscriminate feeding habits with curious and playful nature of young puppy generally leads to ingestion of non-dietary item (Papazoglou *et al.*, 2003; Raghunath *et al.*, 2016; Bharathidasan *et al.*, 2019) [10, 12, 11]. The most frequently reported symptom in cases of gastric foreign body obstruction is vomiting (Rasmussen, 2003) [6]. Plain radiographic survey was done to diagnose and to locate the site of the foreign body in this case. The similar observation was also made by Papazoglou *et al.* (2003) [10] and Bharathidasan *et al.* (2019) [11]. However, exploratory laparotomy was used for definitive diagnosis and subsequent removal of foreign bodies (Hartman *et al.*, 2015; Papazoglou *et al.*, 2010) [3, 10]. As reported by other authors foreign body removal by laparo-gastrotomy is often indicated and has a good prognosis (Bharathidasan *et al.*, 2019) [11], which was found to be of favorable prognosis in the present case as well. As reported by Patil *et al.* (2010) [11] and Halder *et al.* (2018) [4] prognosis of GIT surgery depends upon the duration of presentation, site of obstruction and severity of clinical signs.

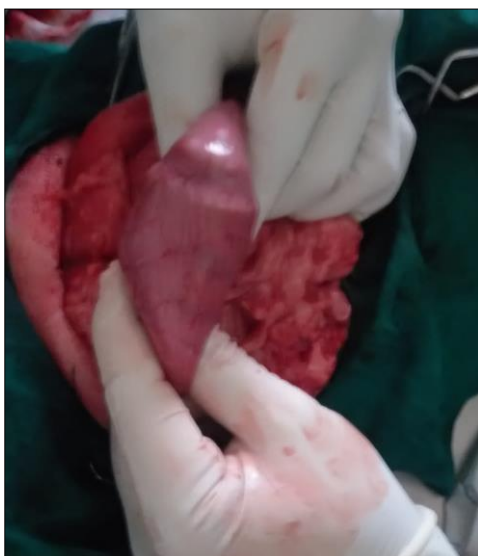


Fig 1: Hard mass palpated in the stomach

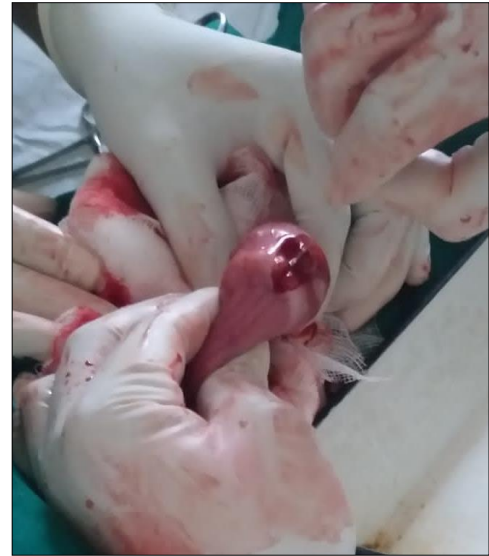

Fig 2: Linear incision made at fundic region

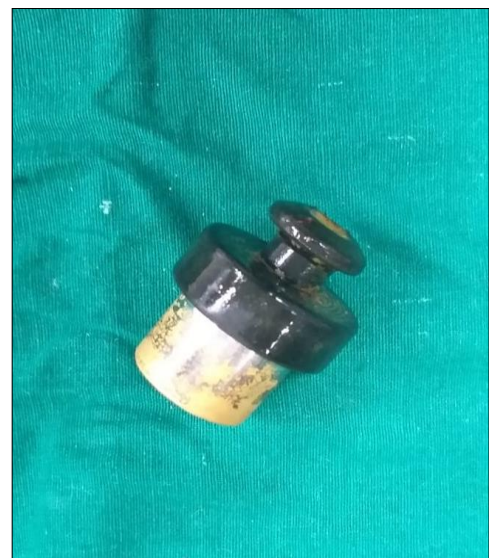

Fig 3: Pressure Cooker Weight

4. Conclusion

In the present case, pet swallowed a pressure cooker weight because of its curious and playful behavior. Since pet was presented soon, the non-linear foreign body was removed by performing gastrotomy. Followed by intravenous fluid therapy and medications, animal recovered uneventfully without any complication.

5. Reference

1. Bharathidasan M, Kokila S, Vishnugurubaran D, Ninu AR, Dharmaceelan S, *et al.* Surgical retrieval of gastric-shuttlecock in Golden Retriever dog. *Int J Agri Sci.* 2019;11(1):7713-7714.
2. Capak D, Brkic' A, Harapin I, Mati Ic' D, Radišić' B. Treatment of the foreign body induced occlusive ileus in dogs. *Vet Arhiv.* 2001;71(6):345-359.
3. Hartman MJ, Kirberger RM, Tordiffe ASW, Boy S, Schoeman JP. Laparoscopic removal of a large abdominal foreign body granuloma using single incision laparoscopic surgery (SILS) and extraction bag in a cheetah (*Acinonyx jubatus*). *Veterinary Record Case Reports.* 2015;3:162.

4. Halder S, Mandal D, Sarkar P. Laparogastrotomy for removal of gastric metallic bolt in spitz dog. *Intas Polivet*. 2018;20(1):135-136.
5. Harari J. *Small Animal Surgery*. William and Wilkins. Pennsylvania; c1996. p. 127-128.
6. Rasmussen LM. *Textbook of small animal surgery*. In: Douglas Slatter, editor. 3rd ed. Saunders, USA; c2003. p. 592-640.
7. Koike T, Otomo K, Kudo T, Sakai T. Clinical cases of intestinal obstruction with foreign bodies and intussusception in dogs. *Jpn J Vet Res*. 1981;29(1-2):8-15.
8. Kumar DD, Ameerjan K, David WA. Gastrointestinal tract obstruction in dogs. *Ind J Vet Sur*. 2000;2(1):43-44.
9. Mahesh V, Kamalakar G, Nagaraja BN. Enterotomy in a Labrador Retriever – A case report. *Int J Livest Res*. 2019;9(12):240-243.
10. Papazoglou LG, Patsikas MN, Rallis T. November intestinal foreign bodies in dogs and cats. *Compend*. 2003;25(11):830-844.
11. Patil DB, Parikh PV, Jhala SK, Tiwari DK, Dar Mud. Gastric foreign bodies in dogs - A report of five cases. *Intas Polivet*. 2010;11(2):297-298.
12. Raghunath M, Sagar PV, Sailaja B, Kumar PR. Surgical correction of intestinal obstruction in a German Shepherd dog. *Scholars J Agri Vet Sci*. 2016;3(3):187-189.