



ISSN Print: 2617-4693
 ISSN Online: 2617-4707
 IJABR 2022; 6(2): 101-103
www.biochemjournal.com
 Received: 08-04-2022
 Accepted: 12-05-2022

Garima Chauhan
 Assistant Professor,
 Department of Biochemistry,
 Chittaranjan National Cancer
 Institute, Kolkata, West
 Bengal, India

Bijita Dutta
 Assistant Professor,
 Department of Pathology,
 ESIPGIMS, ESIC Medical
 College and Hospital, ODC EZ,
 Joka, Kolkata, West Bengal,
 India

Corresponding Author:
Garima Chauhan
 Assistant Professor,
 Department of Biochemistry,
 Chittaranjan National Cancer
 Institute, Kolkata, West
 Bengal, India

Plasma cell dyscrasias with complete loss of immunoglobulin heavy chain expression: A rare case

Garima Chauhan and Bijita Dutta

DOI: <https://doi.org/10.33545/26174693.2022.v6.i2b.143>

Abstract

Background: We are presenting a cases of the monoclonal plasma cell proliferative disorders with complete loss of immunoglobulin heavy chain (HC) expression, which is not LC-MGUS.

Method: Many literatures and text books were being reviewed regarding the classification, presentation and annual progression rate of Light chain myeloma and other dyscrasias expressing only light chain.

Result: Literature data is very scarce. Most of the literatures are batting around LC-MGUS, but not beyond that.

Conclusions: More light should be thrown on this darker area of light chain expressing plasma cell dyscrasias for better management.

Keywords: Heavy chain, Light chain, LC-MGUS, SPEP, SFLCA

Introduction

Multiple myeloma is a plasma cell dyscrasias characterized by monoclonal proliferation of plasma cells and the count of plasma cell is >10% on bone marrow biopsy. Multiple myeloma accounts for 1% of all cancers and approximately 10% of all hematologic malignancies [1]. In about 15% of the MM patients, there is complete loss of heavy chain expression, but these patients produce large amounts of light chains [2]. These patients are commonly referred as light-chain (LC) MM/LC-MGUS. We are presenting a Light chain myeloma with high % of plasma cells in the marrow and complete loss of heavy chain which is a rare finding. The prognosis of such patient is poorer compared to other forms of MM. Literature and research work on Light chain myeloma is very scanty.

Methods

Many literatures and text books were being reviewed regarding the classification, presentation and annual progression rate of Light chain myeloma and other dyscrasias expressing only light chain.

Presentation of case

A 65 year old male patient c/o of occasional back pain visited SSKM, Kolkata OPD in June 2022. After routine checkup patient was send for biochemical, pathological and radiological investigations. Radiological examination revealed diffuse osteopenia, multiple lytic lesions in vertebral bodies, ribs, sternum, b/l femur, humerus, and pelvic bones. Normocytic normochromic anemia found on peripheral blood smear. CT guided FNAC was suggestive of plasma cell neoplasm. During Bone marrow aspiration and examination, plasma cell are 60% and cytological features suggestive of plasma cell neoplasia. Histopathological examination report is consistent with plasma cell neoplasm. Patient is referred to CNCI for further management and treatment. Patient is clinically stable occasionally complaining of backache. Besides routine biochemical and hematological test; SPEP, IFE, SFLCA, Slide review and Block review was done. SPEP -Characteristic monoclonal peak is not found. Possibility of M spike in beta 1 region. IFE –is suggestive of monoclonal kappa light chain.

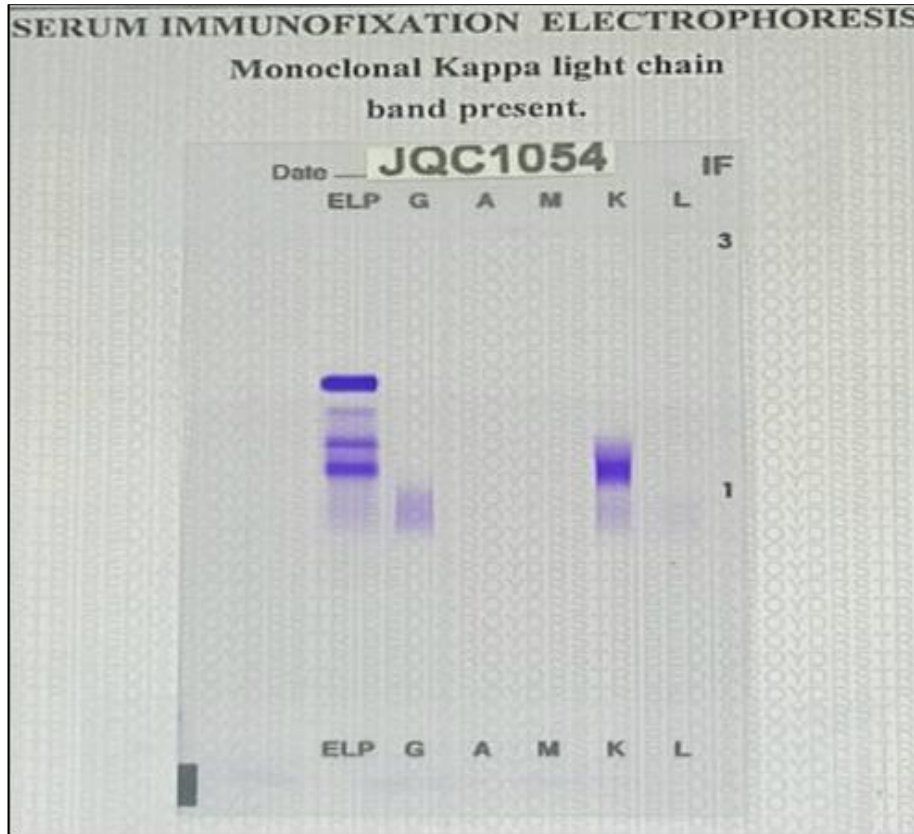


Fig 1: Serum Protein electrophoresis and Immunofixation

Discussion of case

As per the revised International Myeloma Working Group criteria for the diagnosis of multiple myeloma and related disorders {1} - Light-chain MGUS consists only of monoclonal light chains. It is defined by an abnormal free light chain ratio and an increase of involved light chain with complete loss of heavy chain expression. The plasma cell content is < 10%, and there is no end-organ damage attributable to the plasma cell disorder. {3-4} Most of the cases of plasma cell disorder expressing only light chain found in our day today practice are categorized as Light Chain MGUS. But this case is not fulfilling the diagnostic criteria for Light Chain MGUS; as the plasma cell % in the bone marrow is 60% and presence of end organ damage / CRAB criteria positive; so it is not Light chain MGUS. How else we can label this clinical entity. We searched many literature and found only one reference for light chain myeloma in WHO classification of tumours of Haematopoietic and Lymphoid Tissues.

Results

As per the Diagnostic criteria ^[4], patient fulfills the criteria of LC-PCM, as the % of plasma cell in bone marrow is 60% and positive CRAB criteria. LC-MGUS has annual rate of progression of 0.3%, while LC-SPCM has annual rate of progression of 5% in the first 5 years. While no data is available for LC-PCM ^[4].

Conclusion

Literature data for Light Chain Myeloma are very scanty. Most of the data talk about Light Chain-MGUS, but no light has been thrown upon Light Chain myeloma not fulfilling the criteria of Light Chain –MGUS. Light Chain Myeloma has poorer prognosis and different annual progression rate to myeloma than MGUS.

Consent

Written informed consent was obtained from the patient for the publication of this report and any accompanying images.

Conflicts of interest

Authors have no conflict of interest.

Acknowledgments

I pay my sincere thanks to Dr. Namrata Maity (Assistant Professor, Department of Pathology, Chittaranjan National Cancer Institute, Kolkata) for her help in the review of related literature.

References

1. Rajkumar SV, Dimopoulos MA, Palumbo A, Blade J, Merlini G, Mateos MV, *et al.* International Myeloma Working Group updated criteria for the diagnosis of multiple myeloma. *The lancet oncology.* 2014;15(12):e538-e548.
2. Kyle A. International Myeloma Working Group. Criteria for the classification of monoclonal gammopathies, multiple myeloma and related disorders: a report of the International Myeloma Working Group. *British Journal of Haematology.* 2003;121(5):749-757. PMID:12780789.
3. Rosiñol L, Beksac M, Zamagni E. Expert review on soft-tissue plasmacytomas in multiple myeloma: definition, disease assessment and treatment considerations. *British Journal of Haematology.* 2021;194(3):496-507, Online ahead of print.
4. LeNoir B, Bruner ET, Denlinger CE, Gibney BC. Extramedullary plasmacytoma of the right main bronchus. *The Annals of Thoracic Surgery.* 2019;108(2):e119-e120.