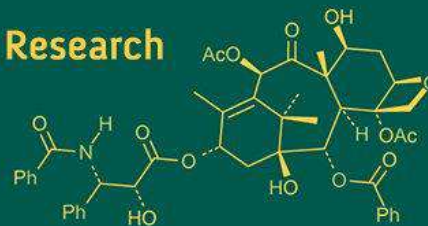
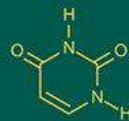
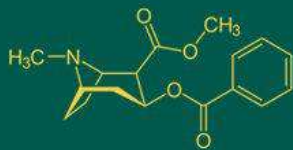


International Journal of Advanced Biochemistry Research



ISSN Print: 2617-4693
ISSN Online: 2617-4707
IJABR 2018; 2(1): 25-29
www.biochemjournal.com
Received: 17-11-2017
Accepted: 21-12-2017

Lames M-Othman
Department of Chemistry,
Faculty of Science, Port Said
University, Egypt

Ahmed K-Hassan
Department of Zoology,
Faculty of Science, Port Said
University, Egypt

Atef E-Abd Elbaky
Department of Chemistry,
Faculty of Pharmacy, Port
Said University, Egypt

Mohamed A-Mahmoud
Department of Chemistry,
Faculty of Science, Port Said
University, Egypt

Anticancer effect of the ethanol extract of *Annona muricata* L. leaves and fruit in cancer induced mice

Lames M-Othman, Ahmed K-Hassan, Atef E-Abd Elbaky and Mohamed A-Mahmoud

Abstract

Objective: The present study was carried out to evaluate the anticancer property of ethanol extract of *Annona muricata* L. Leaves and fruit against Ehrlich ascites carcinoma in Swiss albino mice.

Materials and Methods: The experimental animals were divided into five groups. Group I: (Normal group) Normal mice were received (0.2 ml Saline), Group II: (Cancer group) 20 mice were intraperitoneally received EAC cells (2×10^6 cells/mouse I.P.), Group III: (EAC + leaves extract) 20 mice were orally treated after 48 hours from injection of EAC cell with a dose of 200mg/kg body weight daily for 9 consecutive days, Group IV: (EAC + fruit extract) mice were orally treated after 48 hours from injection of EAC cell with a dose of 200mg/kg body weight daily for 9 consecutive days, Group V: (EAC+ cisplatin), 20 mice were intraperitoneally treated with cisplatin after 48 hours from injection with EAC at a daily dose of 2 mg/kg body weight for 9 consecutive days. Total experimental period was 11 days, after 24 h from the last dose, 8 mice in each group were anesthetized by diethyl ether and sacrificed for the histopathological examination of liver tissue.

Results: The extracts showed residual tumor growth on the surface of the liver without infiltration and mild inflammation.

Conclusion: From the result it can be found that the ethanol extract of *Annona muricata* L. Leaves and fruit showed anticancer effect when compared to the tumor group.

Keywords: *Annona muricata*, Ehrlich ascites carcinoma, mice, cisplatin

Introduction

Cancer is a multi-step disease incorporating physical, environmental, metabolic, chemical and genetic factors (Sumithra *et al.*, 2014) ^[1]. It's occurs when changes in a group of normal cells within the body lead to uncontrolled growth causing a lump called a tumour. If left untreated, tumours can grow and spread into the surrounding normal tissue, or to other parts of the body via the blood stream and lymphatic systems and can affect the nervous, digestive and circulatory systems (Anand *et al.*, 2008) ^[2]. Over 60% of currently used anticancer agents are derived in one way or another from natural sources, including plants, marine organisms and microorganisms (Newman *et al.*, 2003) ^[3]. So, there is a growing interest in the pharmacological evaluation of various natural products used in traditional medicine, Flavonoids, terpenoids, and steroids have received considerable attention in recent years due to their diverse pharmacological properties including antioxidant and antitumor activity (Alvarez *et al.*, 2014) ^[4].

Annona muricata is a species of the Annonaceae family that has been widely studied in the last decades due to its therapeutic potential. All parts of *A. muricata* tree are used in natural medicine including the stem, leaf, root, fruit and seeds (Sundarrao *et al.*, 1993) ^[5]. The medicinal uses of *A. muricata* are especially for treatment of inflammation, cancer, rheumatism and neuralgia (Atawodi *et al.*, 2011). *A. muricata* is native to the warmest tropical areas in South and North America and is now widely distributed throughout tropical and subtropical parts of the world including India, Malaysia, Nigeria, Australia and Africa (Adewole *et al.*, 2006) ^[7]. It lives at altitudes below 1200 m above sea level, with temperatures between 25 and 28 °C, relative humidity between 60 and 80%, and annual rainfall above 1500 mm (Coria-Téllez *et al.*, 2016) ^[8]. *A. muricata* is an evergreen, terrestrial, erect tree reaching 5–8 m in height and features an open, roundish canopy with large, glossy dark green leaves. The tree has large individual and solitary yellowish or greenish-yellow in colour flowers on woody stalks (pedicels). The edible fruits of the tree are large, oval or

Correspondence

Lames M-Othman
Department of Chemistry,
Faculty of Science, Port Said
University, Egypt

heart-shaped and green in color, and frequently irregular lopsided composite sour sop fruit is derived from the fusion of many fruit lets with average weight 4 kg in some countries (Gavamukulya *et al.*, 2017) ^[9]. The present study was carried out to evaluate the antitumor activity of *A. muricata* against Ehrlich ascites carcinoma (EAC) in Swiss albino mice.

Materials and methods

Collection of plant material & preparation of extract

Fresh leaves and fruit of *A. muricata* were collected in the month of March in 2016 from Al-Nobaria, EL-Behera, Egypt. The leaves and fruit were identified by the Taxonomist/curator of Botany Department, Faculty of Science, Port-Said University. Fresh leaves and fruit were cleaned with distilled water before dried at 60°C for one week in the oven, dried leaves and fruit were milled into powder form in a waring blender. The dried powder of leaves and fruit were macerated in 70% ethanol for 48h (with occasional shaking) and filtered through four sheets of gauze then two times by filter paper. The alcoholic solution obtained was concentrated using rotary evaporator under reduced pressure.

Experimental animals

This study was performed on 88 of female Swiss mice about 25-30g weight. Mice were obtained from the National Research Cairo, Egypt. Animals were housed in separate plastic cages under controlled condition of temperature, humidity and 12hr light dark cycle. Animals were fed with standard diet and given water ad libitum through specific nipple for one week of acclimation period prior to the experimental work.

Animal grouping

Group I: (Normal control group), Normal mice were received 0.2 ml saline daily for 11 consecutive days.

Group II: (Positive control group), 20 mice were intraperitoneally received EAC cells (2×10^6 cells/mouse).

Group III: (Leaf extract treated group), 20 mice were orally treated with leaf extract after 48 hours from injection with EAC cell at a daily dose of 200mg/kg body weight for 9 consecutive days (De Sousa *et al.*, 2010) ^[10]. **Group IV:** (Fruit extract treated group), 20 mice were orally treated with fruit extract after 48 hours from injection of EAC cell with at a daily dose of 200mg/kg body weight for 9 consecutive days (De Sousa *et al.*, 2010) ^[10]. **Group V:** (Cisplatin treated group), 20 mice were intraperitoneally treated with cisplatin after 48 hours from injection with EAC at a daily dose of 2 mg/kg body weight for 9

consecutive days (El-Nagar, 2011) ^[11].

Total experimental period was 11 days, after 24 hours from the last treatment dose, 8 mice of each group were anesthetized by diethyl ether and sacrificed, liver tissues were collected and fixed in 10% formalin for histological examination.

Results

Normal control group

Figure (A): Showed normal liver tissue with preserved architecture, normal liver formed of hepatocytes with abundant cytoplasm and smaller nuclei arranged in cell cords in lobular architecture separated by thin wall blood sinusoids. Their lining epithelium consists of flat endothelial cells and the cytoplasm is acidophilic with basophilic regions.

Cancer group

Figures (B) and (C): Showed extensive growth of malignant Ehrlich carcinoma cells on the outer surface of the liver in which presented as groups. Sheets of cells showing high nucleocytoplasmic ratio with enlarged hyper chromatic nuclei and nuclear pleomorphism. Liver tissue showed marked hydropic degeneration of hepatocytes and infiltration by tumor cells to liver tissue with marked inflammatory reaction.

Leaf group

Figures (D) and (E): Represent residual tumor growth on the surface of the liver without infiltration. Tumor showed moderate necrosis and few apoptotic bodies. Hepatocytes showed moderate hydropic degeneration with mild congestion of liver tissue. Also, treated EAC-bearing mice revealed restored normal lobular architecture, while very few hepatocytes showed shrunken deeply stained nuclei.

Fruit group

Figure (F): Illustrated minimal evidence of tumor growth with liver tissue showed moderate hydropic degeneration of hepatocytes and moderate congestion with mild inflammatory infiltrate. All findings indicate marked regression of tumor and good response due to necrosis, apoptosis.

Cisplatin group

Figure (G): Showed that there no evidence of tumor growth. Liver tissue showed marked hydropic degeneration of hepatocytes and moderate congestion with marked severe inflammatory infiltrate (indicate hepatic damage and hepatotoxicity).

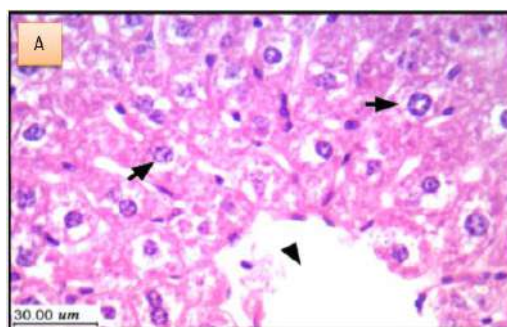


Fig (A): Showing normal liver tissue architecture, normal hepatocytes with abundant cytoplasm and small nuclei arranged in cell cords in lobular architecture separated by thin wall blood sinusoids (short arrow) and central vein (arrowhead). Their lining epithelium consists of flat endothelial cells and the cytoplasm is acidophilic with basophilic region.

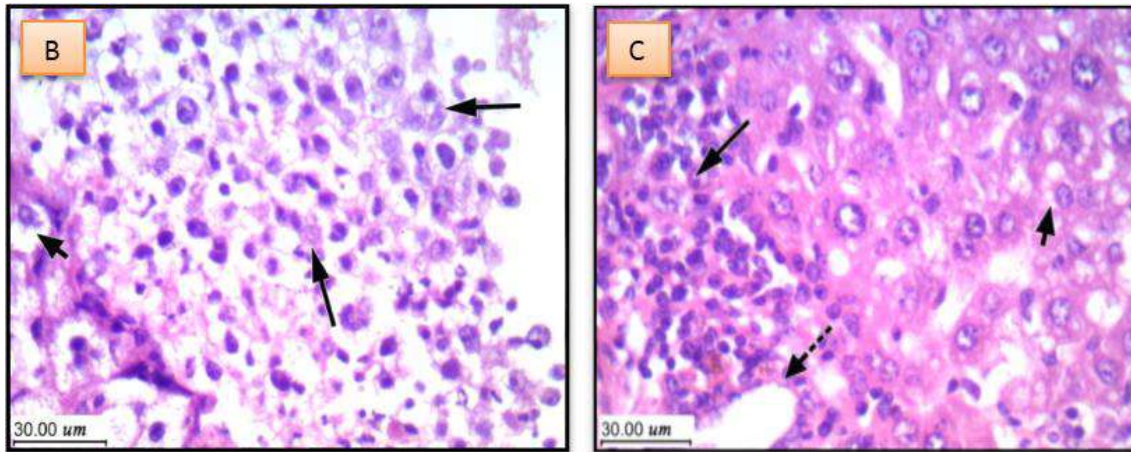


Fig (B): showed extensive growth of malignant Ehrlich carcinoma cells (long arrows) on the outer surface of the liver with hydropic degeneration of hepatocyte (short arrow).
Fig (C): showed extensive growth of malignant Ehrlich carcinoma cells (long arrow) on the outer surface of the liver and infiltration by tumor cells to liver tissue with inflammatory reaction (dashed arrow) and also showed marked degeneration (short arrow).

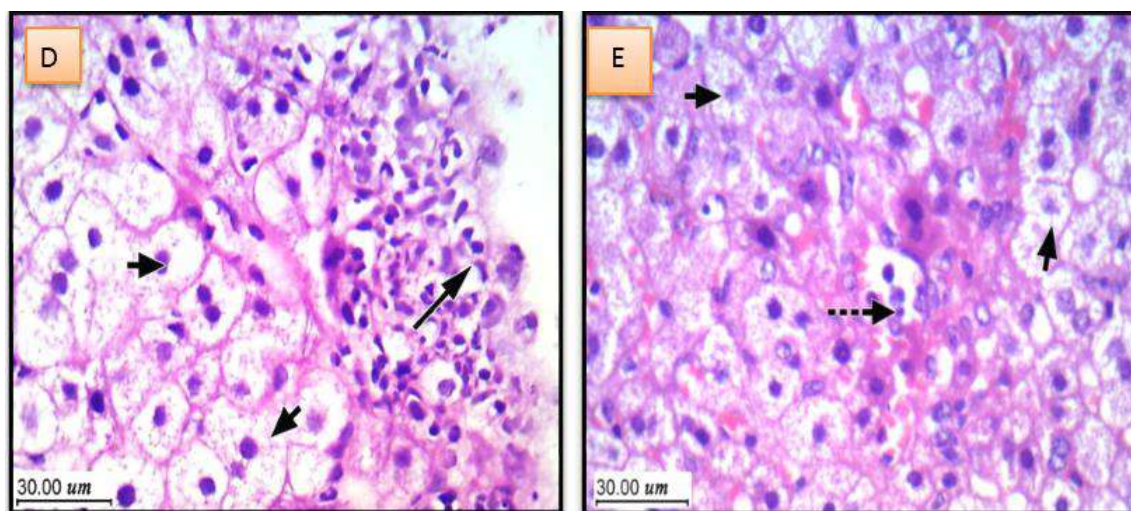


Fig (D): showed residual tumor growth on the surface of the liver (long arrow) without infiltration, tumor showed moderate necrosis and few apoptotic bodies. Hepatocytes with moderate hydropic degeneration and mild congestion of liver tissue (short arrow).
Fig (E): showed minimal tumor growth on the surface of liver (dashed arrow) without infiltration. Tumor showed moderate necrosis and few apoptotic bodies. Hepatocytes showed moderate hydropic degeneration with mild congestion of liver tissue (short arrow).

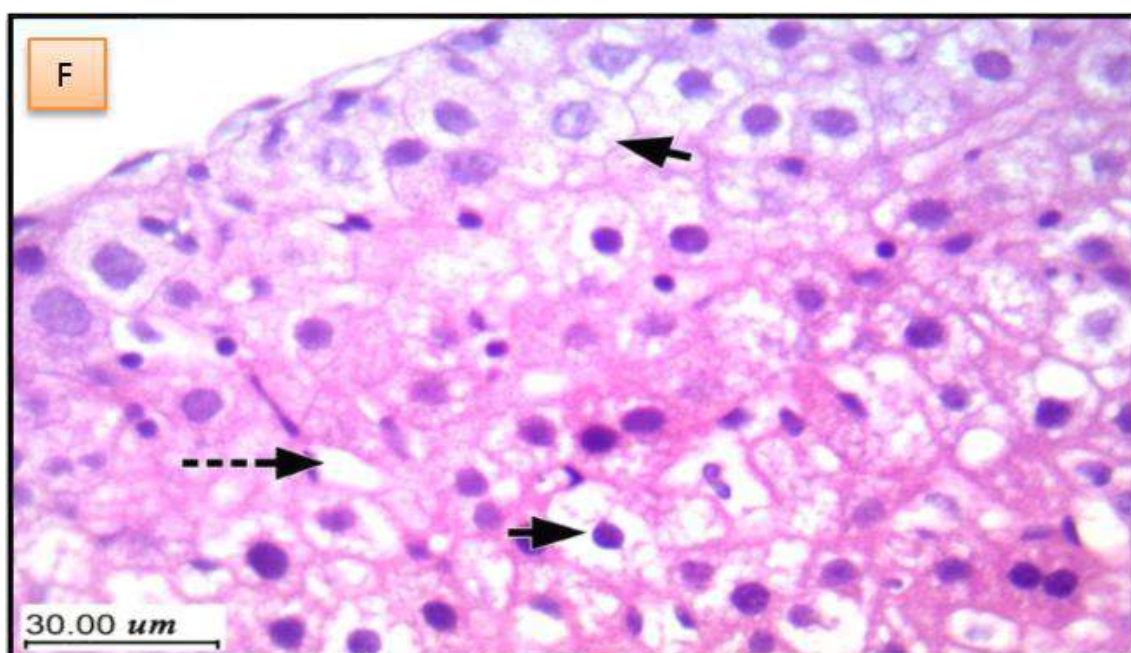


Fig (F): showed minimal evidence of tumor growth with liver tissue (dashed arrow), moderate hydropic degeneration of hepatocytes (short arrow) and moderate congestion with mild inflammatory infiltrate.

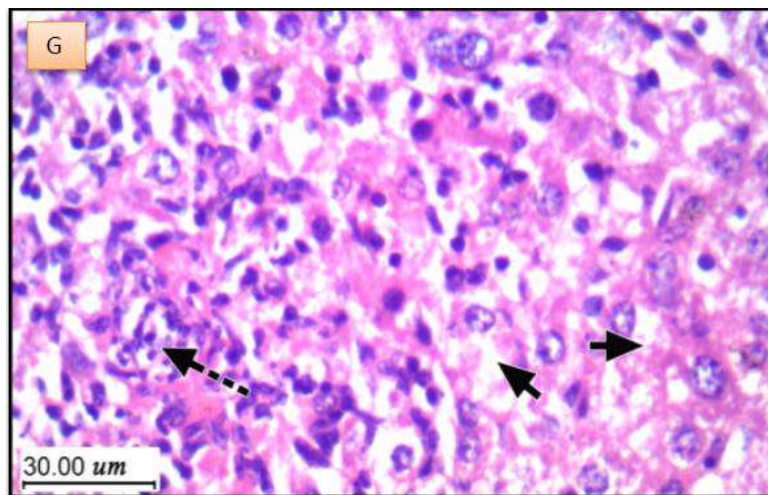


Fig (G): liver tissue showed marked hydropic degeneration of hepatocytes (short arrow), moderate congestion with marked severe inflammatory infiltrate (dashed arrow) and evident hepatotoxicity.

Discussion

In the present work, the histopathological examination of liver in cancer group showed extensive growth of malignant Ehrlich carcinoma cells on the outer surface of the liver in which presented as groups. Marked inflammatory reaction was noticed. This is suggested may be due to migration of EAC tumor cells to liver parenchyma through ascites fluid that cause liver carcinoma, major organs of EAC bearing mice showed significant cellular degeneration/regeneration due to carcinogenesis (Islam *et al.*, 2014) ^[12].

Leaf and fruit extracts treated groups represent residual tumor growth on the surface of the liver without infiltration and mild inflammation. This group revealed restored normal lobular architecture, while very few hepatocytes showed shrunken deeply stained nuclei. This is suggested to be due to hepatoprotective role of *A. muricata*. These results were in agreement with those of (Coria-Te' llez *et al.*, 2016 and Samin *et al.*, 2016) ^[13].

Cisplatin treated group showed that there no evidence of tumor growth. While, Liver tissue showed marked hydropic degeneration of hepatocytes and moderate congestion with marked severe inflammatory infiltrate (indicate hepatic damage and hepatotoxicity). This is suggested to be due to hepatotoxic effect of cisplatin on the liver, this is in agreement with (Yu *et al.*, 2009) ^[14]. Also, this was accompanied with elevated liver enzymes ALT and AST activities in comparison with normal control group.

Reference

1. Sumithra P, Gricilda Shoba F, Vimala G, Sathya J, Sankar V, Saraswathi R. Anticancer activity of Annona squamosa and Manilkara zapota flower extract against MCF-7 cell line. *Der Pharmacia Sinica*. 2014; 5(6):98-104.
2. Anand P, Kunnumakara AB, Sundaram C, Harikumar KB, Tharakan ST, Lai OS *et al.* Cancer is a preventable disease that requires major lifestyle changes. *Pharmaceutical Research*. 2008; 25(9):2097-2116.
3. Newman DJ, Cragg GM, Snader KM. Natural products as sources of new drugs over the period 1981-2002. *Journal of Natural Products*. 2003; 66(7):1022-1037.
4. Alvarez-Suarez JM, Gasparrini M, Forbes-Hernández TY, Mazzoni L, Giampieri F. The composition and biological activity of honey: a focus on Manuka honey. *Foods*. 2014; 3(3):420-432.
5. Sundarrao K, Burrows I, Kuduk M, Yi YD, Chung MH, Suh NJ *et al.* Preliminary screening of antibacterial and antitumor activities of Papua New Guinean native medicinal plants. *International journal of Pharmacognosy*. 1993; 31(1):3-6.
6. Alawode TT. An overview of the anti-cancer properties of some plants used in traditional medicine in Nigeria. *International Research Journal of Biochemistry and Bioinformatics*. 2013; 3(1):7-14.
7. Adewole SO, Caxton-Martins EA. Morphological changes and hypoglycemic effects of *Annona muricata* linn. (Annonaceae) leaf aqueous extract on pancreatic β -cells of streptozotocin-treated diabetic rats. *African Journal of Biomedical Research*. 2006; 9(3):173-181.
8. Coria-Téllez AV, Montalvo-González E, Yahia EM, Obledo-Vázquez EN. *Annona muricata*: A comprehensive review on its traditional medicinal uses, phytochemicals, pharmacological activities, mechanisms of action and toxicity. *Arabian Journal of Chemistry*, 2016. (<http://dx.doi.org/10.1016/j.arabjc.2016.01.004>). In press.
9. Gavamukulya Y, Abou-Elella F, Wamunyokoli F, AEI-Shemy H. Phytochemical screening, anti-oxidant activity and *in vitro* anticancer potential of ethanolic and water leaves extracts of *Annona muricata* (Graviola). *Asian Pacific Journal of Tropical Medicine*. 2014; 7(1):355-363.
10. De Sousa OV, Vieira GDV, De Pinho JDJR, Yamamoto CH, Alves MS. Antinociceptive and anti-inflammatory activities of the ethanol extract of *Annona muricata* L. leaves in animal models. *International Journal of Molecular Sciences*. 2010; 11(5):2067-2078.
11. El-Naggar SA. Lack of the beneficial effects of mirazid (Commiphora molmol) when administered with chemotherapeutic agents on Ehrlich ascetic carcinoma bearing mice. *Adv. Biol. Res*. 2011; 5(4):193-199.
12. Islam F, Ghosh S, Khanam JA. Antiproliferative and hepatoprotective activity of metabolites from *Corynebacterium xerosis* against Ehrlich ascites carcinoma cells. *Asian Pacific Journal of Tropical Biomedicine*. 2014; 4:284-292.

13. Samin B, Fachrial E, Refilda Chaidir Z, Almahdy. Protective Effect of Aqueous Extract of *Annona muricata* Leaves against copper induced hepatotoxicity in experimental rats. *Research Journal of Pharmaceutical Biological and Chemical Sciences*. 2016; 7(6):880-885.
14. Yu YN, Chen H, Li Y. Effect of bicyclol on Cisplatin-Induced hepatotoxicity in the hepatocarcinoma 22 tumour-bearing mice. *Basic and Clinical Pharmacology and toxicology*. 2009; 104(4):300-305.