

ISSN Print: 2617-4693
 ISSN Online: 2617-4707
 IJABR 2018; 2(1): 21-24
 www.biochemjournal.com
 Received: 15-11-2017
 Accepted: 19-12-2017

Lames M-Othman
 Department of Chemistry,
 Faculty of Science, Port Said
 University, Egypt

Ahmed K-Hassan
 Department of Zoology,
 Faculty of Science, Port Said
 University, Egypt

Atef E-Abd Elbaky
 Department of Chemistry,
 Faculty of Pharmacy, Port
 Said University, Egypt

Mohamed A-Mahmoud
 Department of Chemistry,
 Faculty of Science, Port Said
 University, Egypt

Antitumor activity of *Annona muricata* L. fruit and leaves in Ehrlich's ascites carcinoma cell- treated mice

Lames M-Othman, Ahmed K-Hassan, Atef E-Abd Elbaky and Mohamed A-Mahmoud

Abstract

Purpose: The main goal of this study was aimed to evaluate the antitumor effect of *A. muricata* extract of both leaves and fruit in EAC-bearing mice model in comparison with a standard therapeutic agent, cisplatin.

Methods: The antitumor activity of the ethanol extracts of *Annona muricata* were evaluated against Ehrlich ascites carcinoma (EAC) tumor in mice at dose of 200mg/kg body weight orally. Mice were divided into five groups. Group I: (Normal group) mice were received (0.2 ml Saline), Group II: (Cancer group) 20 mice were intraperitoneally received EAC cells (2×10^6 cells/mouse I.P.), Group III: (EAC + leaves extract) 20 mice were orally treated after 48 hours from injection of EAC cell with a dose of 200mg/kg body weight daily for 9 consecutive days, Group IV: (EAC + fruit extract) mice were orally treated after 48 hours from injection of EAC cell with a dose of 200mg/kg body weight daily for 9 consecutive days, Group V: (EAC+ cisplatin), 20 mice were intraperitoneally treated with cisplatin after 48 hours from injection with EAC at a daily dose of 2 mg/kg body weight for 9 consecutive days. Total experimental period was 11 days, after 24 h from the last dose, 8 mice in each group were anesthetized by diethyl ether and sacrificed for the histopathological examination of Kidney tissue.

Results: Administration of the extracts resulted in that *A. muricata* has protective role on the management of histopathological changes occurred in cancer induced mice.

Conclusion: The results suggest that the ethanol extract of *Annona muricata* L. Leaves and fruit showed anticancer effect when compared to the tumor group.

Keywords: *Annona muricata*, Ehrlich ascites carcinoma, mice, cisplatin

Introduction

Cancer is a group of diseases where cell growth is aggressive and abnormal, invasive, and may be metastasizes many times and finally leads to death (Tongyoo, 2010) [1]. Multidisciplinary scientific investigations are making best efforts to combat this disease, but the sure-shot, perfect cure is yet to be brought into world medicine (Balachandran and Govindarajan, 2005) [2]. Cancer can be treated with surgery, radiation, chemotherapy, hormone therapy or biological therapy. Due to lack of effective drugs, cost of chemotherapeutic agents, and the side effects of anticancer drugs, cancer can be a cause of death. Therefore, efforts are still being made to search for effective naturally occurring anticarcinogens that would lessen or prevent the cancer development (Karayil, 2016) [3]. Natural products have served us well in combating cancer, the main sources of these successful compounds are microbes and plants from the terrestrial and marine environments, the microbes serve as a major source of natural products with antitumor activity (Demain and Vaishnav, 2011) [4].

Annona muricata commonly known as graviola or soursop belongs to the family of Annonaceae and is the most tropical semi deciduous tree with the largest fruits of the Annona genus (Alawode, 2013) [5]. *A. muricata* is native to the warmest tropical areas in North and South America and is now widely distributed throughout subtropical and tropical parts of the world including: Malaysia, India, Nigeria, Australia and Africa (Adewole *et al.*, 2006) [6]. *A. muricata* has a number of biological activities such as antifungal, anti-bacterial, anti-malarial and antioxidant. Furthermore, it has been showed to have anti-cancer properties on multi-drug resistant cancer cell lines (Vieira *et al.*, 2010 and Luna *et al.*, 2006) [7, 9, 8].

Correspondence
Lames M-Othman
 Department of Chemistry,
 Faculty of Science, Port Said
 University, Egypt

Materials and Methods

Experimental animals

88 of female Swiss mice about 25-30g weight were used in this study. They were housed in separate stainless cages under controlled condition of temperature, humidity and 12hr light dark cycle. Animals were permitted with standard diet and given water ad libitum through specific nipple for one week of acclimation period prior to the experimental work.

Plant material and preparation of the extract

Fresh leaves and fruit of *Annona muricata* were collected in the month of March in 2016 from Al-Nobaria, EL-Behera, Egypt. The fresh plant materials were washed with clean water, dried at 60C° for one week in the oven, dried leaves and fruit were milled into powder form in a waring blender. The dried powder of leaves and fruit were macerated in 70% ethanol for 48h (with occasional shaking) and filtered through five sheets of gauze then two times by filter paper. The alcoholic solution obtained was concentrated using rotary evaporator under reduced pressure.

Animal groups

Mice were divided into five groups

First group: (normal control group): Normal mice were received 0.2 ml saline daily for 11 consecutive days.

Second group: (Positive control group), 20 mice were intraperitoneally received EAC cells (2×10^6 cells/mouse).

Third group: (EAC+ leaves extract): 20 mice were orally treated with leaves extract after 48 hours from injection with EAC cell at a daily dose of 200mg/kg body weight for 9 consecutive days (De Sousa *et al.*, 2010) [9].

Fourth group: (EAC+ fruit extract), 20 mice were orally treated with fruit extract after 48 hours from injection of EAC cell with at a daily dose of 200mg/kg body weight for 9 consecutive days (De Sousa *et al.*, 2010) [9].

Fifth group: (EAC+ cisplatin), 20 mice were intraperitoneally treated with cisplatin after 48 hours from injection with EAC at a daily dose of 2 mg/kg body weight for 9 consecutive days (El-Nagar, 2011) [10].

Total experimental period was 11 days, at the end of the study period, 8 mice in each group were anesthetized by diethyl ether and sacrificed. Kidney tissues were collected and put in 10% formalin for histopathological examination.

Results

Control group

As shown in figure (A), normal kidney tissue is formed of glomeruli and tubules. Glomeruli showed capillary tuft, thin Bowman's space and mesangial cells, while tubules lined by columnar cells with abundant esinophilic cytoplasm almost filling tubule lumen (proximal tubules) and other tubules lined by low cubical cells with patent lumen (distal tubules) separated by intesrtitium showed thin blood vessels.

Cancer group

Figures (B) and (C) showed extensive growth of malignant Ehrlich carcinoma cells on the outer surface of the kidney presented as multiple layers. Groups and sheets of cells showing high nucleocytoplasmic ratio with enlarged hyper

chromatic nuclei and nuclear pleomorphism. There is no infiltration of the organ by tumor cells. Kidney tissue showed marked hydropic degeneration of tubular epithelium with marked swelling of cytoplasm and marked congestion of vessels with areas of hemorrhage and focal cystic changes.

Leaf group

Figures (D) and (E) showed mild residual tumor growth on the kidney surface without infiltration. Tumor showed mild necrosis and few apoptotic bodies. Kidney showed minimal hydropic degeneration of epithelium tubules with mild congestion. All findings indicate marked regression of tumor and good response to necrosis and apoptosis.

Fruit group

As shown in figures (F) and (G), there is no evidence of tumor growth in Kidney tissue and only showed mild hydropic degeneration of tubules. Few viable tumor with marked regression of tis sized forming only 2-3 layers of cells with evidence of marked necrosis was shown. There is moderate hydropic degeneration of tubules and moderate congestion. All findings indicate marked regression of tumor and good response to necrosis and apoptosis.

Cisplatin group

Figure (I) showed that there is no evidence of tumor growth. Kidney tissue showed marked hydropic degeneration of tubules with marked congestion of vessels. In this group glomeruli showed focal increased cellularity of mesangial cells, focal shrinkage and hyalinosis. All findings indicate marked regression of tumor and good response, but with marked secondary changes on kidney due to toxicity.

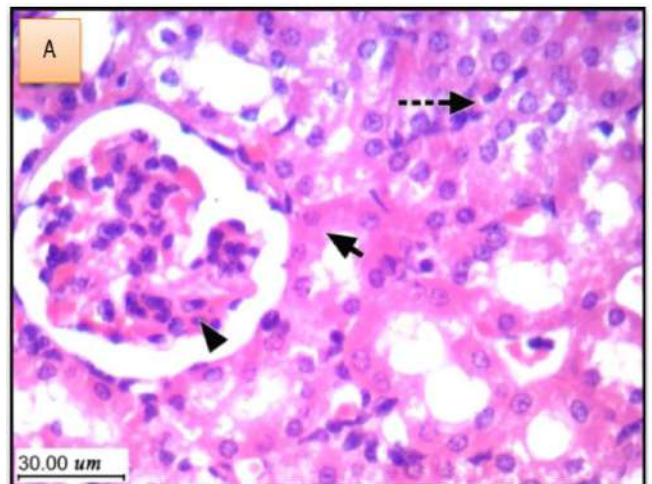


Fig (A): Normal kidney tissue formed of glomeruli and tubules. Glomeruli showed capillary tuft, thin Bowman's space and mesangial cells(arrow head), while tubules (short arrow) lined by columnar cells with abundant esinophilic cytoplasm almost filling tubule lumen (proximal tubules) while other tubules lined by low cubical cells with patent lumen (distal tubules) separated by intesrtitium showed thin blood vessels (dashed arrow).

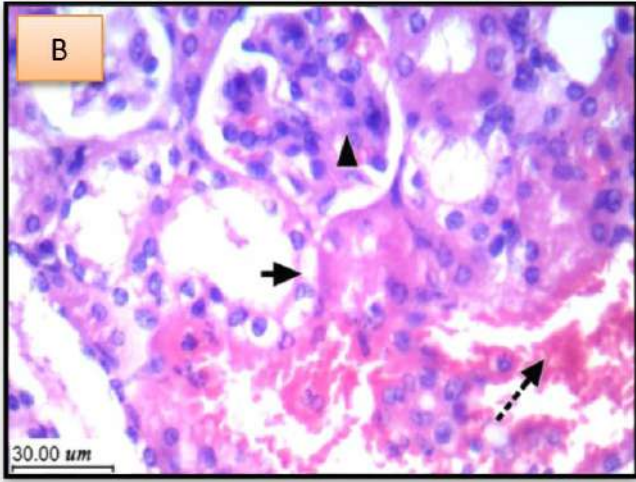


Fig (B): Kidney tissue showed marked hydropic degeneration (short arrow) of tubular epithelium with marked swelling of cytoplasm and marked congestion of vessels with areas of hemorrhage and focal cystic changes (dashed arrow).

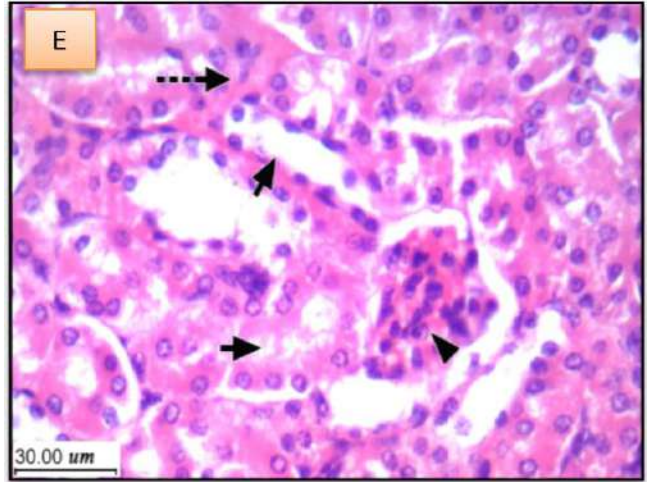


Fig (E): there is no evidence of tumor growth with kidney tissue. Minimal hydropic degeneration (short arrow) of tubular epithelial cells with mild congestion is showed. Pathological changes in glomerulus (arrowhead) with few hemorrhage in vessel (dashed arrow).

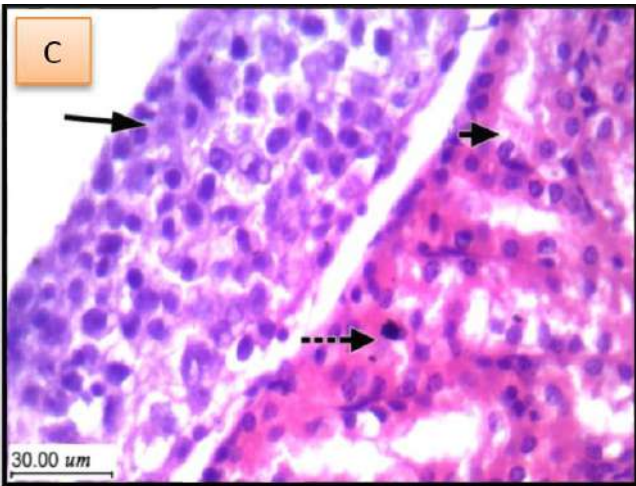


Fig (C): showed extensive growth of malignant Ehrlich carcinoma cells (long tumor) on the outer surface of the kidney presented as multiple layers. Kidney tissue showed marked hydropic degeneration (short arrow) of tubular epithelium and marked congestion of vessels with areas of hemorrhage and focal cystic changes (dashed arrow).

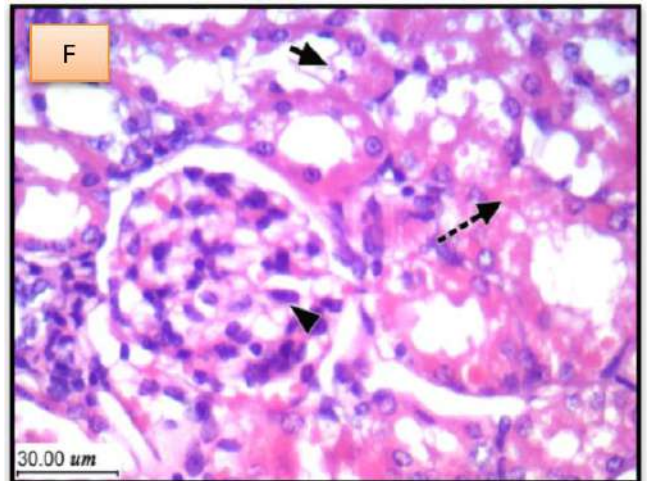


Fig (F): showed there are no evidence of tumor growth in Kidney tissue and mild hydropic degeneration of tubules (short arrow) with pathological change in glomerulus (arrow head) and minimal inflammation in vessel (dashed arrow).

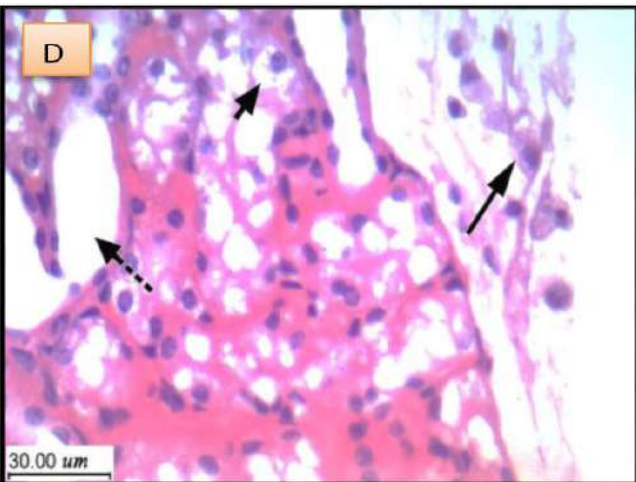


Fig (D): showed mild residual tumor growth on the surface (long arrow) of the kidney without infiltration. Tumor showed mild necrosis and few apoptotic bodies. Kidney showed minimal hydropic degeneration (short arrow) of tubules epithelium with mild congestion.

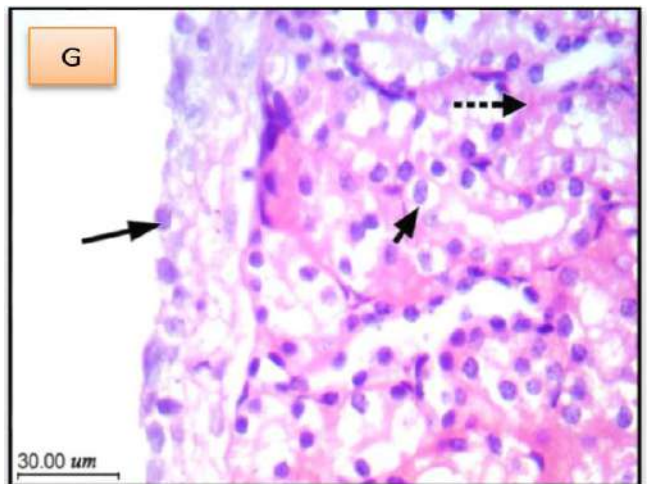


Fig (G): showed viable tumor (long arrow) with marked regression of tis sized forming only 2-3 layers of cells with evidence of marked necrosis, there is moderate hydropic degeneration of tubules and moderate congestion (short arrow) with minimal hemorrhage in vessel (dashed arrow).

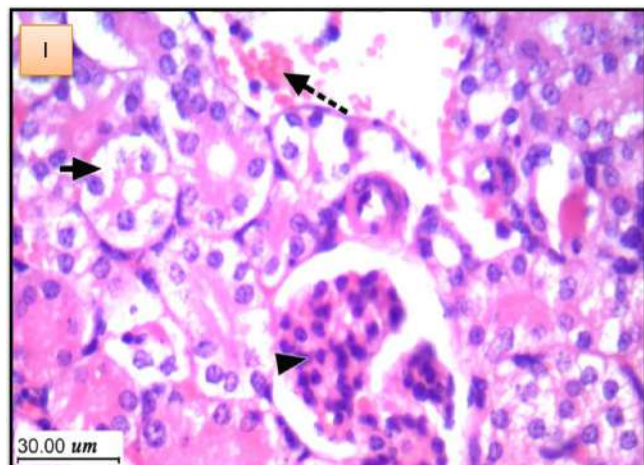


Fig (I) showed there is no evidence of tumor growth. Kidney tissue showed marked hydropic degeneration of tubules with marked congestion of vessels (short arrow). In this group glomeruli showed focal increased cellularity of mesangial cells, focal shrinkage and hyalinosis (arrow head) that indicate marked regression of tumor and good response, marked secondary changes on kidney due to toxicity.

Discussion

In the current study, histopathological examination of kidney in cancer group showed extensive growth of malignant Ehrlich carcinoma cells on the outer surface of the kidney, marked hydropic degeneration of tubular epithelium and marked congestion of vessels with areas of hemorrhage and focal cystic changes. This may be attributed to increased mitotic division of tumor cells with high body fluid with drawal and the capillary permeability, which permit the escape of plasma proteins into peritoneal cavity (Garrison *et al.*, 1987) ^[11]. This finding was accompanied with elevated creatinine level.

In leaf and fruit extracts treated groups, microscopic examination of kidney showed mild residual tumor without infiltration, minimal hydropic degeneration of epithelium tubules with mild congestion and good response to necrosis and apoptosis. This could be suggested due to *A. muricata* anti-tumorigenic and anti-metastatic activities on internal tumors in murine models (Torres *et al.*, 2012) ^[12]. This indicates that treatment with *A. muricata* extract has protective effect against kidney damage due to presence of saponins, flavonoids, tannins and glycosides that contribute to the treatment of various diseases, including treatment for kidney impairment (Arthur *et al.*, 2011) ^[13].

In cisplatin treated group, histopathological examination showed that there is no evidence of tumor growth, marked hydropic degeneration of tubules with marked congestion of vessels and increased glomerular cellularity of mesangial cells. These findings indicate marked regression of tumor and good response, but with marked secondary changes on kidney. These changes may be due to suggested toxicity of cisplatin which inhibited proliferation and increased the percentage of dead cells compared to the untreated groups. These results were in agreement with those reported by (Shirmanova *et al.*, 2017) ^[14]. Also, it was reported that cisplatin is a strong cellular toxin and nephrotoxicity is one of the most important complications of this drug in clinical and experimental models, which can be progressive in more than 50% of cases (Filipski *et al.*, 2008) ^[15].

References

1. Tongyoo A. Targeted therapy: novel agents against cancer. *J Med Assoc Thai.* 2010; 93(Suppl 7):311-323.
2. Balachandran P, Govindarajan R. Cancer—an ayurvedic perspective. *Pharmacological Research.* 2005; 51(1):19-30.
3. Karayil S. Cytotoxic activity of *Annona muricata* L. leaf extract. *European Journal of Biomedical and Pharmaceutical sciences.* 2016; 3(7):527-530.
4. Demain AL, Vaishnav P. Natural products for cancer chemotherapy. *Microbial Biotechnology.* 2011; 4(6):687-699.
5. Alawode TT. An overview of the anti-cancer properties of some plants used in traditional medicine in Nigeria. *International Research Journal of Biochemistry and Bioinformatics.* 2013; 3(1):7-14.
6. Adewole SO, Caxton-Martins EA. Morphological changes and hypoglycemic effects of *Annona muricata* Linn. (Annonaceae) leaf aqueous extract on pancreatic β -cells of streptozotocin-treated diabetic rats. *African Journal of Biomedical Research.* 2006; 9(3):173-181.
7. Viera GHF, Mourão JA, Ângelo ÂM, Costa RA, Vieira RHSDF. Antibacterial effect (*in vitro*) of *Moringa oleifera* and *Annona muricata* against Gram positive and Gram negative bacteria. *Revista do Instituto de Medicina Tropical de São Paulo.* 2010; 52(3):129-132.
8. Luna JDS, De Carvalho JM, De Lima MRF, Bieber LW, Bento EDS, Franck X *et al.* Acetogenins in *Annona muricata* L. (Annonaceae) leaves are potent molluscicides. *Natural Product Research.* 2006; 20(3):253-257.
9. De Sousa OV, Vieira GDV, De Pinho JDJR, Yamamoto CH, Alves MS. Antinociceptive and anti-inflammatory activities of the ethanol extract of *Annona muricata* L. leaves in animal models. *International Journal of Molecular Sciences.* 2010; 11(5):2067-2078.
10. El-Naggar SA. Lack of the beneficial effects of mirazid (Commiphora molmol) when administered with chemotherapeutic agents on Ehrlich ascetic carcinoma bearing mice. *Adv. Biol. Res.* 2011; 5(4):193-199.
11. Garrison RN, Galloway RH, Heuser LS. Mechanisms of malignant ascites production. *Journal of Surgical Research.* 1987; 42(2):126-132.
12. Torres MP, Rachagani S, Purohit V, Pandey P, Joshi S, Moore ED *et al.* Graviola: a novel promising natural-derived drug that inhibits tumorigenicity and metastasis of pancreatic cancer cells *in vitro* and *in vivo* through altering cell metabolism. *Cancer Letters.* 2012; 323(1):29-40.
13. Arthur FKN, Woode E, Terlabi EO, Larbie C. Evaluation of acute and subchronic toxicity of *Annona muricata* (Linn.) Aqueous extract in animals. *European Journal of Experimental Biology.* 2011; 1(4):115-124.
14. Shirmanova MV, Druzhkova IN, Lukina MM, Dudenkova VV, Ignatova NI, Snopova LB *et al.* Chemotherapy with cisplatin: insights into intracellular pH and metabolic landscape of cancer cells *in vitro* and *in vivo*. *Scientific Reports.* 2017; 7(1):1-13.
15. Filipski KK, Loos WJ, Verweij J, Sparreboom A. Interaction of Cisplatin with the human organic cation transporter 2. *Clinical Cancer Research.* 2008; 14(12):3875-3880.